

Detection of Diabetic Retinopathy

Shazadkhalid khan, ChandrashekharJadhav, Abhisheksalunke

¹(Electronics &Telecommunication, PimpriChindhwad college of engineering and research/ SPPU, INDIA)

Abstract: Diabetic Retinopathy (DR) is one of the main causes of blindness and visual impairment in developed countries, stemming solely from diabetes mellitus. Current screening methods using fundus images rely on the experience of the operator as they are manually examined. Automated methods based on neural networks and other approaches have not provided sensitivity or specificity above 85%. This work presents a Image Processing based method that directly identifies hard exudates and dot haemorrhages (DH) from 100 digital fundus images from a graded database of images using standard Image Processing techniques, and clinical observation and knowledge. Sensitivity and specificity in diagnosis are 95-100% in both cases. Positive and negative prediction values (PPV, NPV) were 95-100% for both cases. The overall method is general, computationally efficient and suitable for further clinical trials to test both accuracy and the ability to the track DR status over time.

I. Introduction

Here, we are going to design an algorithm which will help to diagnose diabetic retinopathy using computer vision. Retinopathy is a common cause of visual loss in the world and it is a potentially blinding complication of diabetes that damages the eye's retina. Non-insulin-dependent diabetes mellitus (NIDDM) may be the most rapidly growing chronic disease in the world. Its long-term complications, including retinopathy, nephropathy, neuropathy, and accelerated macro vascular disease, cause major morbidity and mortality. At first, you may notice no changes in your vision. But do not let diabetic retinopathy fool you. It could get worse over the years and threaten your good vision. Diabetic retinopathy is a complication of diabetes that affects the blood vessels of the retina. Growth of new blood vessels, known as proliferative retinopathy, may lead to blindness through haemorrhage and scarring. A deterioration of retinal blood vessels causing loss of blood vessels and leakage into the retina is known as maculopathy and leads to visual impairment and may progress to blindness.

Electrophysiological tests reveal an abnormal function of the visual system in patients with diabetic retinopathy . Visual evoked potential (VEP) has been used in the clinical environment as a diagnostic tool for a long time. VEP is one of the non-invasive tools in analysing diabetic retinopathy. So far not much of the work has been taken up to identify the effect of retinopathy on optical response and variation in the functioning of the optic nerve. Through analysis of evoked potential response of the optical nerve and optical brain centre a way will be paved for early diagnosis of diabetic retinopathy and prognosis during the treatment process.

In general, the clinical use of VEP is based on the peak amplitude and the latencies of the N75, P100, and N145. The amplitude and the latencies of these peaks are measured directly from the signal . This requires precise definition of the starting and the end points. Latency measure depends on the point at which the latency is calculated and usually irregular peaks occur due to background EEG, so that averaging and interpolation are required. Therefore the diagnosis is based on the amplitude and latency in time domain is not alone sufficient. Hence other components should also be taken into consideration. In recent years, many researchers have described a variety of approaches to extract the evoked potentials from the background ongoing EEG. The investigation of the frequency domain characteristics of VEP is an attractive analytic approach because it allows detection of subtle waveform abnormalities that may escape detection with normal latency measurements. The spectral analysis of VEP can yield useful information when it is performed carefully. Classification of the severity of diabetic retinopathy and quantification of diabetic changes are vital for assessing the therapies and risk factors for this frequent complication of diabetes. Current clinical studies use the standardized, validated Wisconsin grading system of retinopathy, which is performed by an experienced ophthalmologist or grader using standard photographs. This method is a time-consuming process which requires significant training and exercise and is vulnerable to observer error.

The artificial neural network (ANN) has been used in a number of different ways in medicine and medically related fields. The principle advantages of ANNs are that they are able to generalize, adapting to signal distortion and noise without loss of robustness, and that they are trained by example and do not require precise description of patterns to be classified or criteria for classification. Computer simulation is well established as a powerful and effective way of modelling health care systems.

II. Identifying Hard Exudates

Exudates are common abnormalities in the retina, and are bright lipid leaked from a blood vessel. The leaked fluid tends to stay close to the puncture yielding a generally well- defined edge suitable for computer analysis (Ege et al, 2000). Therefore, before searching for exudates, an algorithm is developed for automatic detection of the optic disc. In the image, the yellow colour corresponds to a high intensity on the green channel and typically the optic disc contains the majority of the highest green intensities on a given image. Thus, an initial approximation to the optic disc is obtained by sorting the green intensities from the lowest to the highest, and choosing all pixels in the top 0.5% of intensities. This method may also capture some other bright yellow regions like exudates, but the majority will lie on the optic disc. Figure 1 shows the optic disk identified as the largest connected region (LCR) of such dots on this colour channel, as well as the bounding circle created to eliminate it from further consideration in the algorithm.

Pre-processing

All images were converted to a hierarchical data format for pre-processing, data augmentation, and training. Pre-processing involved several steps: images were cropped using Otsu's method to isolate the circular colored image of the retina. Images were normalized by subtracting the minimum pixel intensity from each channel and dividing by the mean pixel intensity to represent pixels in the range 0 to 1. Contrast adjustment was performed using the contrast limited adaptive histogram equalization (CLAHE) filtering algorithm.

Data Augmentation

We augmented the number of images in real-time to improve network localization capability and reduce overfitting. During each epoch, a random augmentation of images that preserve collinearity and distance ratios was performed. We implemented random padding with zeros, zoom, rolling and rotation. These affine transformations are particularly effective when applied to disease class R1 which are the most difficult to grade and fewest in number.

Training and Testing Models

A Deep Learning GPU Training System (DIGITS) with prebuilt convolutional neural networks for image classification facilitated data management, model prototyping and real-time performance monitoring. DIGITS is an interactive system and was first used to build a classification dataset by splitting the Messidor and MildDR fundus folder into training and validation subsets of 1077 and 269 images respectively. The images were cropped to area size 256x256 and used as input data by Imagenet models previously trained for generic classification tasks. This training system, which offered extensive hyperparameter selections, was then used to build model prototypes over 100 epochs requiring approximately 20 minutes each to complete.

Figures and Tables

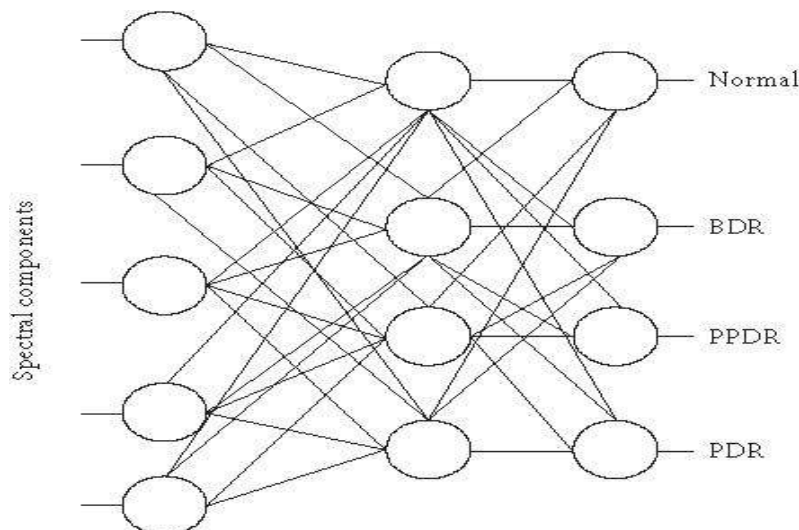


FIG 1: CLASSIFICATION OF IMAGES

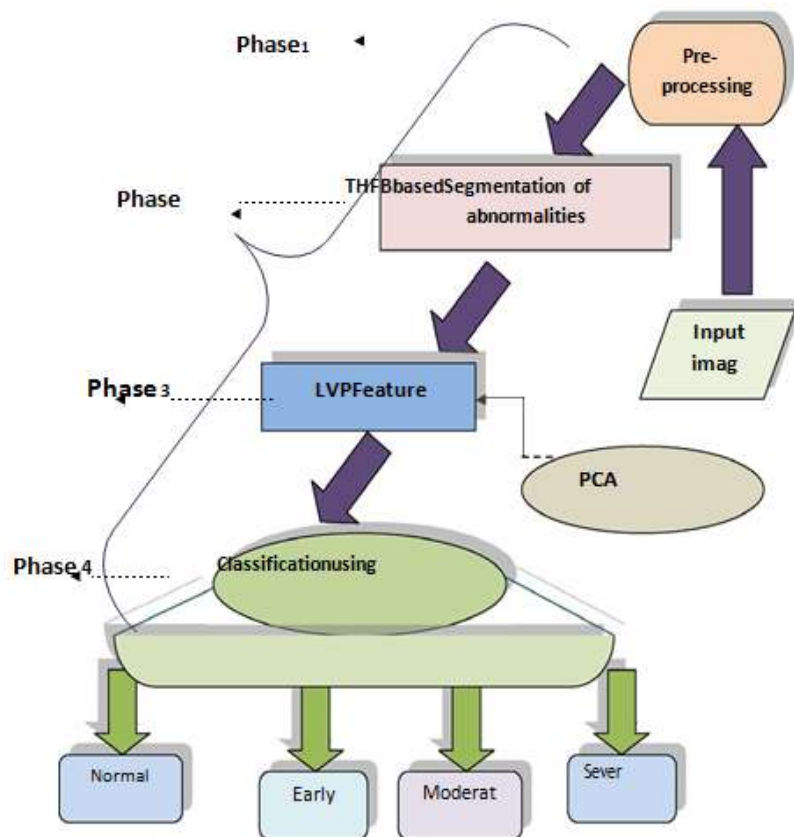


FIG 2: PROPOSED BLOCK DIAGRAM

III. Conclusion

Automatic methods for screening exudates and dot hemorrhages have been developed based on image processing methods that utilize colour, morphology and intensity gradients in fundus photographs. 100 images from a standard database were used to test the methods. For exudate detection, the sensitivity was 96.9% and specificity was 94.9% in terms of whether detecting the presence of DR or not. For dot haemorrhages, the sensitivity was 98.7% due to one false negative and the specificity was 100 %. From visual checks of the images, there were virtually no false exudates or dot haemorrhages detected which suggests the method could be used to accurately track changes over time. However, these results need to be validated in future clinical trials. tin 20 mg on every other regimen had equal effect when compared to daily dose regimen of atorvastatin 40 mg & rosuvastatin 20mg.

References

- [1]. Abramoff, MD Niemeijer, M Suttorp-Schulten, MSA Viergever, MA Russell, SR and Van Ginneken, B (2008). "Evaluation of a System for Automatic Detection of Diabetic Retinopathy From Color Fundus Photographs in a Large Population of Patients With Diabetes," *Diabetes Care*, 31(2):193-198.
- [2]. Chia D, Yap E (2004). "Comparison of the Effectiveness of Detecting Diabetic Eye Disease: Diabetic Retinal Photography Versus Ophthalmic Consultation," *Singapore Medical Journal*, 45:276-279.
- [3]. Ege BM, Hejlesen, OK, Larsen, OV, Moller, K, Jennings, B, Kerr, D and Cavan, DA (2000). "Screening for diabetic retinopathy using computer based image analysis and statistical classification," *Computer methods and programs in Biomedicine*, 62; pp. 165-175
- [4]. ETDRSG (Early Treatment Diabetic Retinopathy Study Research Group) (1991). "Early Photocoagulation for Diabetic Retinopathy," *Ophthalmology*, 98:766-785. and Related Disorders. 2009;7(3):221-230.
- [5]. Fong D, Aiello L, Gardner T, King G, Blankenship G, Cavallerano J, Ferris F, Klein R (2003). "Diabetic Retinopathy," *Diabetes Care*, 26:226-229.
- [6]. Fong D, Aiello L, Gardner T, King G, Blankenship G, Cavallerano J, Ferris F, Klein R (2004). "Retinopathy in Diabetes," *Diabetes Care*, 27:584-587
- [7]. Frame, A.J., Undill, P.E., Cree, M.J., Olson, J.A., McHardy, K.C., Sharp, P.F., Forrester, J.F. (1998). "A comparison of computer based classification methods applied to the detection of microaneurysms in ophthalmic fluorescein angiography." *Diabetes Care*. 2008;31(4):811-822